


PRESENTING CLINICAL SIGNS

DATE History: Pre-anesthetic ECG showed VPCs. FIV positive. No murmur.

8/31/22 ECHOCARDIOGRAPHIC FINDINGS

2D, M-mode, and Doppler study.

PERFORMED BY: Left atrial size is normal. The mitral valve appears normal. Left ventricular wall thickness is normal. Left ventricular dimensions are normal. Left ventricular systolic function is normal. The aorta and aortic valve are normal. Right atrial and right ventricular dimensions are normal. The tricuspid valve appears normal. The pulmonary artery and pulmonic valve are normal. No shunting lesions are visualized. No heartworms are visualized. No pericardial effusion or cardiac masses are seen.

Dr. Meredith Swart

INTERPRETED BY

Keith Blass, DVM,
MS, DACVIM
(Cardiology)

LA/Ao – 1.30
IVSd – 3.7 mm
LVPWd – 3.2 mm
LVIDd – 19.0 mm
LVIDs – 11.9 mm
FS – 37.3%
LVOT – 0.57 m/s
RVOT – 0.95 m/s

PATIENT

Monkey Moorman

SPECIES ASSESSMENT/RECOMMENDATIONS

Normal echocardiogram

Feline

This examination demonstrates no evidence of structural heart disease. As such, no reason for Monkey's VPCs is appreciated in the image set. It's possible that Monkey's FIV could be the cause of his arrhythmia, if the virus has resulted in secondary myocarditis, though no abnormalities consistent with myocarditis were visualized in this exam.

BREED
DSH

Monkey's cardiovascular risk for general anesthesia is mildly to moderately increased based on his arrhythmia, therefore, some precautions should be taken in order to minimize this risk. I recommend avoiding the use of alpha-2 agonists, ketamine, telazol, and, if possible, anticholinergics in the anesthetic protocol. Lidocaine (1 mg/kg slow IV) should be available in case a significant ventricular arrhythmia develops during the procedure.

SEX
MN

No therapy is recommended based on Monkey's echocardiogram.

AGE

9 y

A recheck ECG is recommended in 1-2 months. A recheck echocardiogram is recommended if new physical exam and/or clinical abnormalities suggestive of the presence of structural heart disease develop.

WEIGHT

5.5 kg

HOSPITAL NAME

Swart Veterinary
Imaging

REFERRING VET

Dr. Swart



DATE

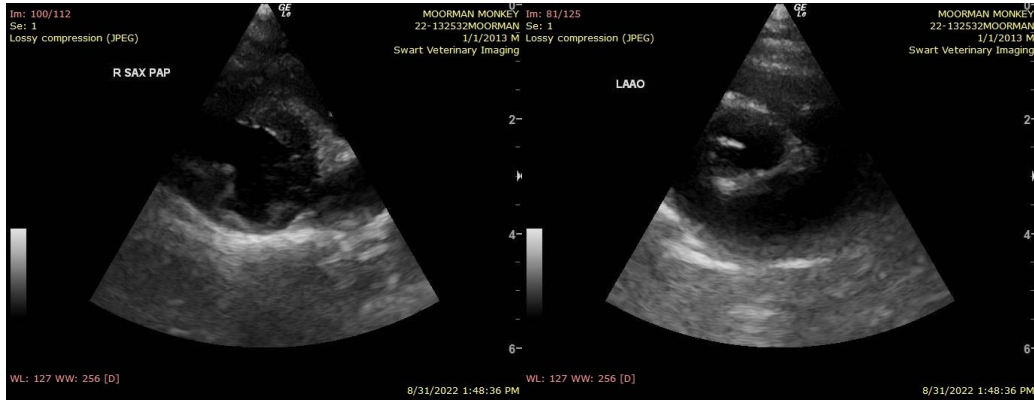
8/31/22

PERFORMED BY:

Dr. Meredith Swart

INTERPRETED BY

Keith Blass, DVM,
MS, DACVIM
(Cardiology)



The information and recommendations provided are based on the images presented by the referring veterinarian. No evaluation can be communicated regarding pathology that was not visible in the image/video clips provided.

PATIENT

Thank you for this referral. If the clinical or image interpretation does not parallel your findings or if I can be of any further assistance please contact me.

Monkey Moorman

Keith Blass, DVM, MS, DACVIM (Cardiology)

KeithBlass@gmail.com

631-804-5754

SPECIES

Feline

BREED

DSH

SEX

MN

AGE

9 y

WEIGHT

5.5 kg

HOSPITAL NAME

Swart Veterinary
Imaging

REFERRING VET

Dr. Swart